

## Microsurgical Nerve Conduit Neurotization to Restore Sensation after Breast Reconstruction Surgery

► Plastic surgeons at Penn Medicine are performing microsurgical neurotization to enhance sensation in the reconstructed breast.

The lateral and anterior intercostal nerves that supply the breast are transected during mastectomy, eliminating potential sources of innervation during later reconstruction surgery. In the absence of neurotization, the reconstructed breast will regain some sensation as a result of nervous migration from surrounding skin and tissue, but this is a gradual and variable process.

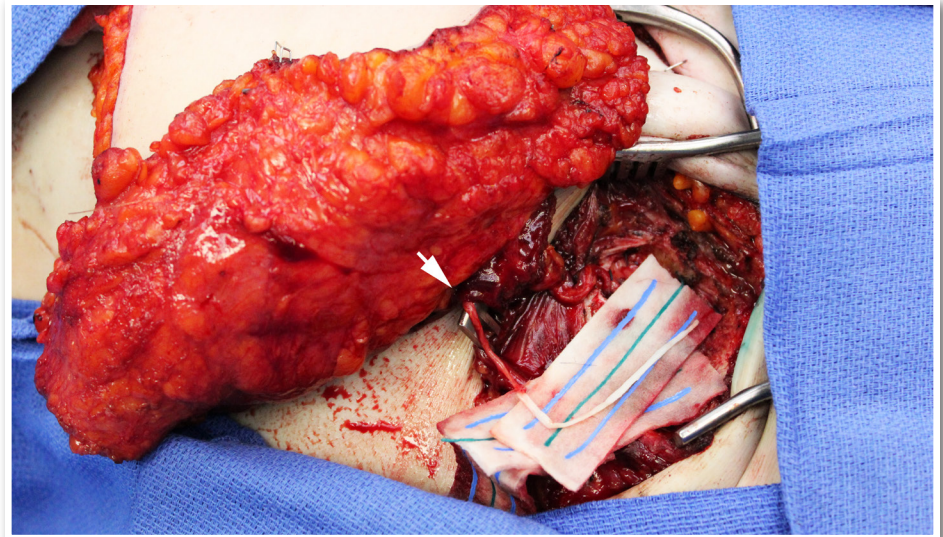
A more rapid and predictable restoration of sensation can be achieved by the innervated abdominal flap procedure. This surgery, which involves direct coaptation of the fourth or fifth intercostal nerve to the T10-T12 thoracoabdominal nerve, has generally been associated with superior quality and quantity of sensation vs. natural sensory return. It has been argued however, that the complexity and added operative time attending neurotization is unjustified given the possibility of natural nerve regeneration.

Penn plastic surgeons have recently introduced neurotization, a method to simplify and improve upon the efficacy of direct coaptation. This approach involves connecting a cutaneous nerve at the fascia of the abdominal flap to the anterior branch of the third intercostal nerve, which appears at the junction of the sternum and third rib.

This nerve is dissected at the sternum and sutured to an allograft conduit customized to permit minimal traction on the nerve, avoiding tension across the repair. The distal end of the conduit is then sutured to the sensory nerve in the flap. The procedure can be completed in about 15 minutes, and involves less resection and positioning than standard neurotization.

Sensory perception at two years following neurotization with nerve conduits has been reported to be significantly better than direct coaptation when performed as above described.

At this time, neurotization is performed for abdominal-based free-flap breast reconstruction, including transverse rectus abdominis myocutaneous (TRAM), deep inferior epigastric perforators (DIEP) and superficial inferior epigastric artery (SIEA) flap breast reconstruction.



► **Figure 1:** DIEP flap breast reconstruction with nerve conduit neurotization (arrow) to enhance sensation in the reconstructed breast.

### CASE STUDY

Mrs. M, a 48-year-old woman with left-sided ductal carcinoma in situ (DCIS), came to Penn Medicine for both her mastectomy and breast reconstruction surgery. Following her surgery and radiation therapy, she chose to have a staged breast reconstruction. During the mastectomy procedure, therefore, Ms. M received a tissue expander beneath the skin and muscles of her chest wall containing a small amount of saline. Four months later, she returned to Penn Plastic Surgery for a deep inferior epigastric perforator (DIEP) flap procedure with nerve conduit neurotization to enhance sensation in the reconstructed breast.

While the recipient site was being prepared in the operating room, a flap of skin and fat was harvested from Mrs. M's lower abdomen. Microdissection was performed at the abdominal fascia to dissect the largest perforators from the flap. A cutaneous donor nerve was then defined and dissected out for later neurotization. At the recipient site, the internal mammary artery and vein were prepared at the third intercostals space for anastomosis to the donor perforators.

The anterior branch of the third intercostal nerve was then identified at the third rib and mobilized. Following successful microsurgical anastomosis of the perforator and mammary vessels, a nerve conduit was introduced to coapt the donor and recipient nerves.

Mrs. M recovered for four days in the hospital and was discharged home. At her 6-month, one year and two year follow-up visits, she noted increasing sensation in the reconstructed breast.

**FACULTY TEAM**

The experienced surgeons in the Division of Plastic Surgery at Penn Medicine offer the most advanced treatment options for patients in need of cosmetic and reconstructive surgery, as well as a comprehensive skin care program. In addition to breast reconstruction, specialty areas include craniofacial reconstruction, congenital anomalies, reconstruction following tumor and trauma, microsurgical techniques, cleft lip and palate surgery, and cosmetic facial and body surgery.

**Performing Breast Reconstruction Surgery at Penn**

**John Fischer, MD**  
*Assistant Professor of Surgery*

**Joshua Fosnot, MD**  
*Assistant Professor of Surgery*

**Suhail K. Kanchwala, MD**  
*Assistant Professor of Surgery*

**Stephen J. Kovach III, MD**  
*Assistant Professor of Surgery*

**David W. Low, MD**  
*Professor of Surgery*

**Joseph M. Serletti, MD, FACS**  
*Henry Royster–William Maul Measey Professor of Surgery*

**Liza C. Wu, MD**  
*Associate Professor of Surgery*

**Micropigmentation Specialist**

Mandy Sauler

**ACCESS**

**Perelman Center for Advanced Medicine**

South Pavilion, 1st Floor  
3400 Civic Center Boulevard  
Philadelphia, PA 19104

**Penn Plastic Surgery Bryn Mawr**

23 Morris Avenue, Suite 219  
Bryn Mawr, PA 19010

**Penn Medicine Washington Square**

800 Walnut Street, 20th floor  
Philadelphia, PA 19107