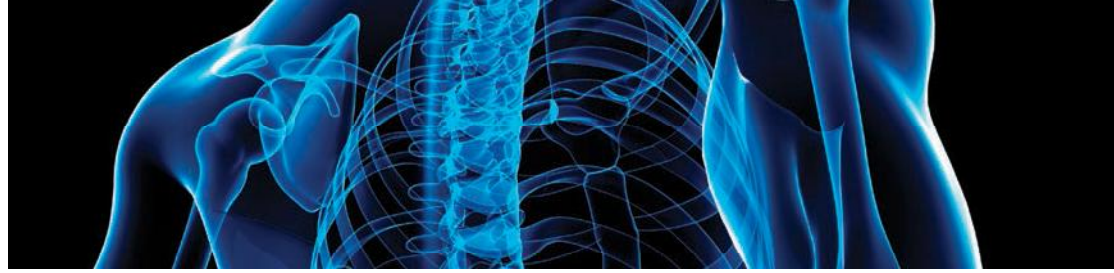

BONE SCALPEL™ ULTRASONIC BONE DISSECTOR: APPLICATIONS IN SPINE SURGERY AND SURGICAL TECHNIQUE GUIDE



Peyman Pakzaban, MD, FAANS

Houston MicroNeurosurgery - Houston, TX

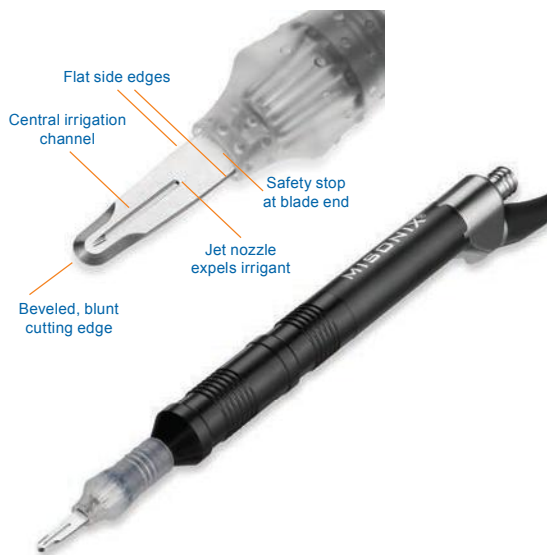Abstract

The Misonix BoneScalpel is a novel ultrasonic surgical device that cuts bone and spares soft tissues. This relative selectivity for bone ablation makes BoneScalpel ideally suited for spine applications where bone must be cut adjacent to dura and neural structures. Extensive clinical experience with this device confirms its safety and efficacy in spine surgery. The aim of this report is to describe BoneScalpel's mechanism of action and the basis for its tissue selectivity, review the expanding clinical experience with BoneScalpel (including the author's personal experience), and provide a few recommendations and recipes for *en bloc* bone removal with this revolutionary device.

Introduction

The advent of ultrasonic bone dissection is as significant to spine surgery today as the adoption of pneumatic drill was several decades ago. Power drills liberated spine surgeons from the slow, repetitive, fatigue inducing, and occasionally dangerous maneuvers that are characteristic of manually operated rongeurs. Now ultrasonic dissection with BoneScalpel empowers the surgeon to cut bone with an accuracy and safety that surpasses that of the power drill.

The greater accuracy of BoneScalpel is a result of the back-and-forth micro-motion of BoneScalpel's thin blade as opposed to the rotary macro-motion of a drill's burr. This permits fine and precise bone cuts not afforded by a drill. In addition, BoneScalpel has two attributes that provide greater safety. First, elimination of rotary motion avoids many of the risks associated with the drill, such as slipping off the cutting surface and entrapping important soft tissues. Second, BoneScalpel cuts bone better than soft tissue. This tissue selectivity, which may seem counter-intuitive at first glance, is extremely useful in spine surgery where the surgeon is routinely faced with the task of cutting bone adjacent to dura.



Mechanism of Action

Ultrasound is a wave of mechanical energy propagated through a medium such as air, water, or tissue at a specific frequency range. The frequency is typically above 20,000 oscillations per second (20 kHz) and exceeds the audible frequency range, hence the name ultrasound. In surgical applications, this ultrasonic energy is transferred from a blade to tissue molecules, which begin to vibrate in response. Whether tissue molecules can tolerate this energy transfer or be destroyed by it depends on the density of the tissue and the frequency of oscillation. Dense tissues, such as bone, are ablated by frequencies in the low ultrasonic range.

The BoneScalpel assembly consists of an ultrasonic generator/irrigation console that connects to a hand-piece bearing a disposable cutting tip (Fig. 1). The cutting tip oscillates back and forth a very small distance at rate of 22,500 times per second (a frequency in the low ultrasonic range). The cutting tip comes in two main varieties (additional ones are being developed): the blade and the shaver tip (Fig. 2). The blade behaves like an ultrasonic micro-osteotome to make well-defined cuts in bone and is used for *en bloc* removal of large pieces of bone. The shaver tip behaves like a non-rotating burr to selectively ablate bone in a small area. The integrated irrigation feature helps remove bone debris and cool the cutting tip.

The BoneScalpel blade's mechanism of action is best understood by analogy to an osteotome (Fig. 3). When an osteotome is struck by a mallet, the energy that is transmitted down the shaft of the osteotome is focused along its narrow tip. This focused energy is then transferred from the tip to a very narrow band of bone, which disintegrates in response, thus creating the leading edge of a cleavage plane in bone.

Much like an osteotome, the blade of BoneScalpel moves forward (and backward) (Fig. 4). However, the amplitude of this movement is much smaller than that of an osteotome (35-300 microns), thus transferring only a small amount of energy to bone with each impact. The very high frequency at which the blade moves back and forth to impact the bone (22.5 kHz) compensates for the small energy of each individual impact, thus resulting in a large transfer of energy to bone at the point of contact. Again, this energy disintegrates a narrow sliver of bone and develops a cleavage plane.

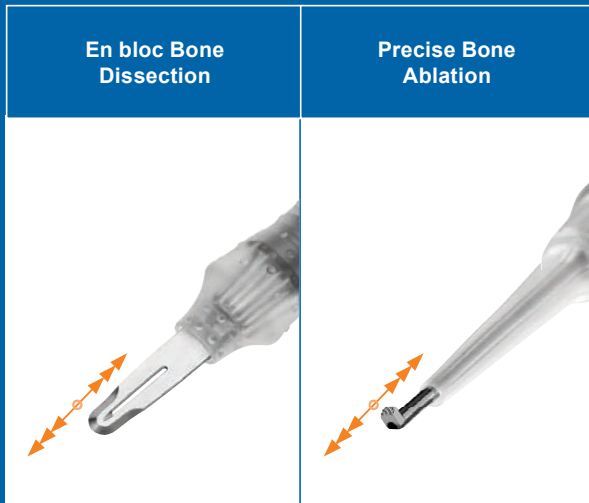


Figure 2. Two bone cutting tips and techniques: The blade (left) is used for *en bloc* bone removal while the shaver tip (right) is used for precise bone ablation.

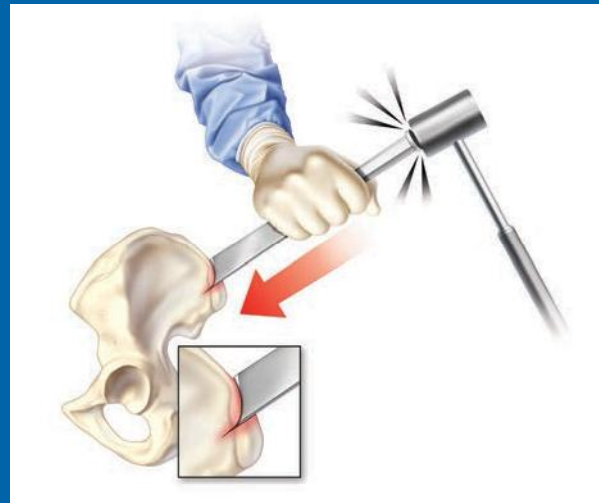

Figure 3. Osteotome mechanism of action

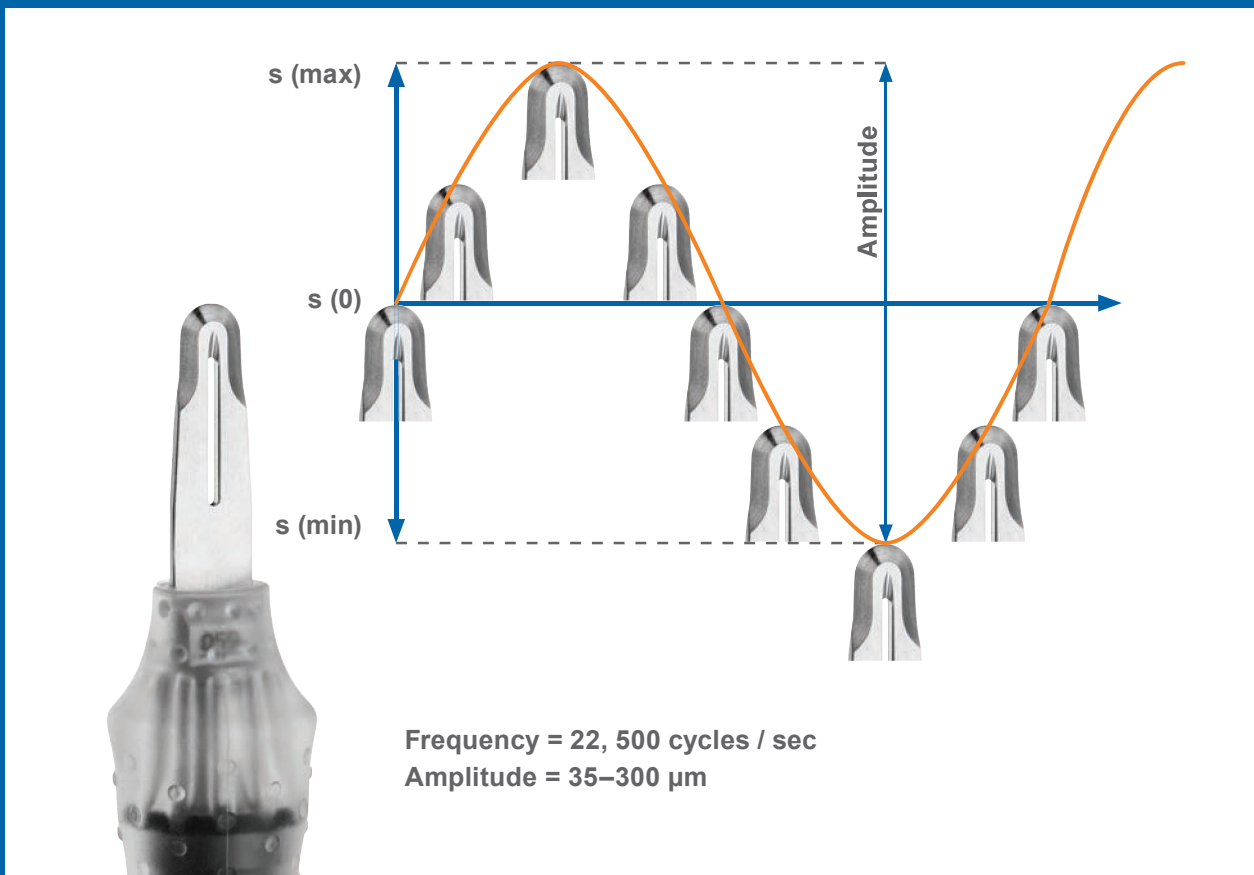


Figure 4. Back-and-forth micro-movement of BoneScalpel blade occurs at 22,500 cycles per second.

Tissue Selectivity

The relative selectivity of BoneScalpel for bone cutting has to do with the relative rigidity of bone compared to soft tissues (Fig. 5). When the blade of BoneScalpel comes in contact with rigid bone, the bone does not bend, deform, or move away from the tip. As a result, a large amount of energy is transferred to a small amount of bone at the point of contact, resulting in destruction of that bone. In contrast, soft tissue structures (such as ligamentum flavum, posterior longitudinal ligament, and dura) can bend, deform, move away, and vibrate upon contact with the blade, thus dampening the energy transfer and protecting the tissue from destruction.

It is important to note that this selectivity is not absolute. With sufficient time and pressure, soft tissues will be cut. Safe and efficient use of BoneScalpel in spine surgery depends on development of a tactile “feel” for penetrating the inner cortex of bone. After this penetration occurs, the blade should come in contact with underlying tissues for a limited time with limited pressure.

Bone Cutting Technique

The analogy to a micro-osteotome whose blade moves back and forth will help the surgeon understand that BoneScalpel cuts more efficiently with downward (axial) pressure rather than side-to-side (lateral) movements. In the author’s experience, a useful strategy for cutting bicortical bone consists of the following 3 steps:

1. Lateral movement with little axial pressure to score the outer cortex of bone to be cut (Fig. 6A).
2. Axial pressure and liberal lateral sweeps to cut through the cancellous mid-portion of the bone (Fig. 6B).
3. Controlled cyclical forward/backward movement with short lateral sweeps to penetrate the inner bone cortex (Fig. 6C). This step primarily involves the use of controlled axial (downward) pressure. Once the surgeon palpates the intended breach of the inner cortex, he withdraws the blade slightly, moves slightly to one side and repeats the sequence. It is important to note that one generally cannot visualize the underlying soft tissues through the thin trough that is created and must rely on tactile feedback. If unsure of having penetrated the cortex, the surgeon can momentarily stop the ultrasonic action, palpate the inner cortex with the BoneScalpel blade, and then resume cutting.

When performing the third step, the BoneScalpel’s relative selectivity for bone cutting provides a good margin of safety, allowing the surgeon to contact the underlying dura. However, it is important for the surgeon to avoid the following pitfalls. First, one must not plunge into the dura. As with any other surgical tool, such plunging may cut the dura and result in neural injury. Second, one should not linger over the dura so as to avoid excessive heat development and a thermal lesion. Once the inner cortex is penetrated, the blade is withdrawn and moved to an adjacent location. Third, one should avoid using this device when dura is likely to be adherent to the inner bone cortex (e.g. in presence of epidural scar or in ossification of posterior longitudinal ligament). In these settings, the dura is at risk, since it cannot move away from the blade of BoneScalpel after the latter *en bloc* penetrates the inner cortex. Furthermore, even if the bone is cut uneventfully, elevating it from the underlying adherent dura is likely to result in dural laceration. Alternatively, one can cut a slice of bone adjacent to the region of epidural scarring, dissect the adherent dura from the undersurface of the adjacent bone, cut another slice of bone in the dissected area and repeat these steps until the desired amount of bone is removed.

Unlike the drill, safe and efficient use of BoneScalpel has a surprisingly short learning curve. When teaching this technique to other surgeons, the author makes the following recommendations:

- Develop a tactile “feel” for BoneScalpel by practicing on a bone specimen. It is important not only to develop a feel for when the inner cortex is penetrated, but also to familiarize oneself with the amount of axial pressure that is required to cut through bone efficiently.
- Palpate with BoneScalpel off. If unsure of whether the inner bone cortex has been penetrated, momentarily stop the bone scalpel and “palpate” the residual bone with the BoneScalpel blade.
- Plan the cuts to be made. Unlike manual rongeurs or power drills, BoneScalpel removes bone *en bloc*. It is, therefore, imperative that one plans in advance and defines the boundaries of the bone to be cut. At the end of this article, several cutting “recipes” for various spine projects are provided.
- Divide the project into smaller pieces. Although it may appear counter-intuitive, it is often more efficient to divide a large bone cutting project (e.g. removing a whole lumbar lamina) into two or three smaller pieces. Doing so will improve visualization of the thicker or deeper portions of the bone to be cut and will facilitate elevation of cut bone blocks from the underlying ligaments.

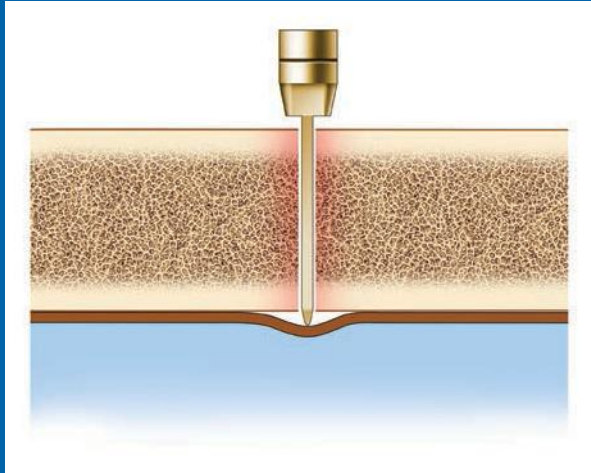


Figure 5. Differential energy transfer from the blade to rigid bone vs. the underlying flexible soft tissue is the basis for BoneScalpel's tissue selectivity.

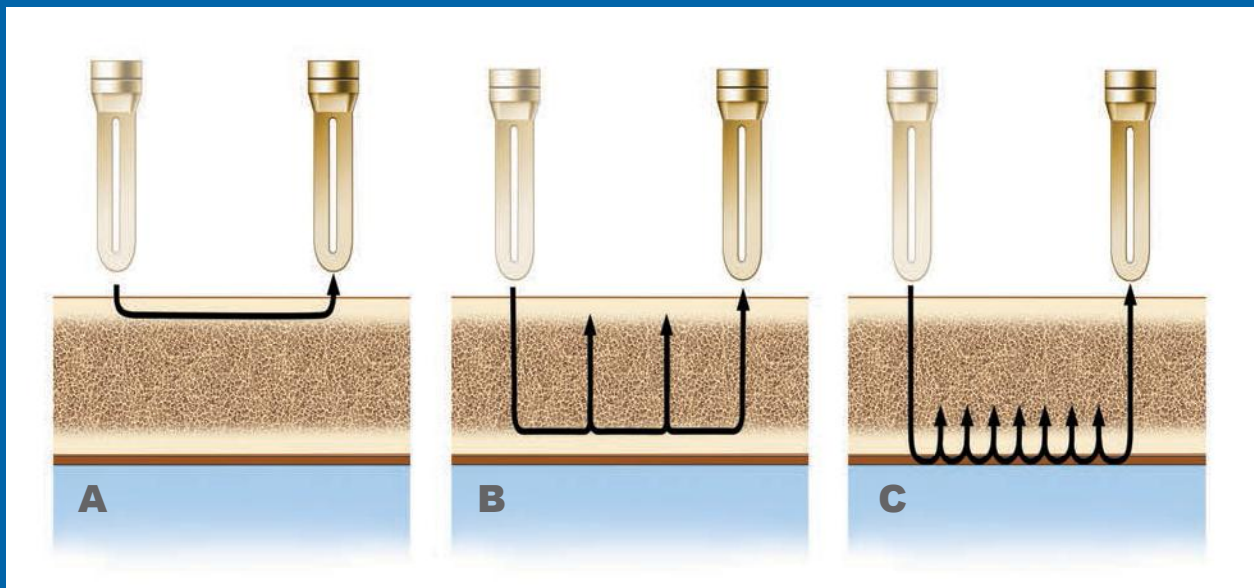


Figure 6. A three-step technique for cutting bicortical bone involves: A. Scoring the outer cortex, B. Cutting rapidly through the soft cancellous bone, and C. Repeatedly penetrating the inner cortex with controlled axial pressure.

Comparison with Other Bone Removal Technologies

BoneScalpel's attributes are compared to other bone cutting tools in some detail in Table 1. It is important to recognize that these technologies are not competing but complementary. Just as power drills and Kerrison rongeurs are used side-by-side to remove bone and ligament in the same operation, BoneScalpel is fast becoming another indispensable tool in the spine surgeon's toolbox to tackle surgical tasks not performed as well by the other devices. Specifically, in comparison to high-speed drills, BoneScalpel offers several distinguishing features. The absence of rotary movement is a very significant advantage that minimizes slippage, shatter, and tissue entrapment (weed-whacker phenomenon). The relative tissue selectivity for bone vs. soft tissue allows brief contact with dura. The ability to make fine cuts in bone allows efficient removal of relatively large blocks of bone. Bone debris is minimized and the harvested blocks of bone can be used as bone graft in fusion procedures.

Surgeons have also noted significantly less bleeding in operations performed with BoneScalpel (1). Ultrasound has coagulative effects and BoneScalpel can cauterize the small venous channels in cancellous bone. This heat is quickly dissipated by the BoneScalpel's efficient irrigation mechanism. More importantly, *en bloc* (vs. piecemeal) removal of bone minimizes the duration (and therefore the total volume) of bleeding from epidural veins while the bleeding is controlled. In the author's experience, this significantly reduces epidural bleeding in facetectomies performed for transforaminal fusion (Fig. 9).

Clinical Reports

An expanding body of literature describes the successful use of BoneScalpel in clinical applications ranging from laminoplasty to harvest of osteocutaneous flaps for oncologic reconstructive surgery. Before reviewing these clinical reports, it is appropriate to begin with an experimental study in an animal model.

Sanborn et al. at University of Pennsylvania compared laminectomies using hand instruments and cutting burrs to those performed with BoneScalpel in a sheep model (2). No significant clinical or behavioral differences were found between the two groups. Intraoperative neurophysiological monitoring revealed no differences between the groups. Histological examination of the cut bone revealed similar amounts of inflammatory and reparative changes. A single durotomy was noted in each group. Operative times for the experimental group were significantly shorter than those for the control group. The authors concluded that BoneScalpel made precise cuts over short distances and reduced operative time. Welch, the principle investigator in that study, who went on to develop an extensive clinical experience with BoneScalpel, has shared his clinical impression, confirming many of the aforementioned attributes of this device including soft tissue preservation, thinner cuts, increased speed by virtue of *en bloc* bone removal, and reduced bleeding (1).

The most significant clinical reports on the use of BoneScalpel in spine surgery have come out of Johns Hopkins University and Texas Back Institute. Recinos et al. of Johns Hopkins were the first to report the use of BoneScalpel to perform osteoplastic laminoplasties in 2 pediatric patients with intradural tumors in 2009 (3). They noted that the fine bone cuts produced by this device allowed closer re-approximation of bone edges after replacement of the laminae, thus improving the opportunity for bone healing. This would be significant in the pediatric population, where rapid osteointegration after laminoplasty would protect against progressive kyphotic deformity. The same group reported its expanded experience with BoneScalpel in adult and pediatric laminoplasties in AANS/CNS Spine Section meeting in 2011 (4) and recently published a comprehensive case series in Neurosurgery (5). In the latter report, Parker et al. retrospectively analyzed 40 patients (age range: 4 - 80 years) who underwent osteoplastic laminoplasties

BoneScalpel Technology Comparison

	Powered			Manual	
	BoneScalpel	High-speed Drill	Micro Saw	Osteotome	Kerrison Punch
Cutting frequency	22,500 strokes/sec (1,300,000 strokes/min)	~ 1,300 rotations/sec (80,000 rpm)	~ 300 cps (20,000 cpm)	single stroke	single punch
Handpiece configuration	straight / angled	straight / angled	straight / angled	straight	angled
Cutting mode	longitudinal	rotational	longitudinal or transverse	longitudinal	jawlike rotation
Tip types	multiple osteotome + shaver + drill (coming)	multiple burr + drill	single sagittal + oscillating saws	single osteotomes	single punches
Tip cooling	direct to active edge	indirect / ancilliary	indirect / ancilliary	n/a	n/a
Precision	very high	high	high	high	high
Minimal kerf size	0.5 mm	2 mm	0.3 mm	2-3 mm	2-3 mm
Axial tip displacement	very low	medium	medium	very high	n/a
Lateral tip walking / straying	very low	very high (walking/skyving)	very high (bilateral straying)	n/a	n/a
Tip inertia	very low	very high	high	very high	n/a
Tip stop/start/stop	near instantenous	delayed	delayed	cannot be stopped after strike	n/a
Impact force	very low	low	medium	very high	high
Risk of tip slippage	very low	very high risk of tissue injury	low	very high	none
En bloc bone dissection for harvest	very good	poor	moderate	very good	n/a
Frontal bone dissection	very good	very good	poor	very good	n/a
Lateral bone dissection	Limited with blade, very good with shaver	very good	good	n/a	moderate
Fine bone ablation	very good	very good	n/a	n/a	n/a
Bone debris	minimal not visible & flushed out	very high	minimal	n/a	very high bite chunks - require assistance w/ every actuation
Tissue selectivity	very high	n/a	n/a	n/a	n/a
Soft tissue interaction	gentle / atraumatic (reduced on shaving surfaces)	very aggressive	very aggressive	aggressive	aggressive
Tissue grabbing/tearing	none	very aggressive risk of tissue injury	aggressive on teeth	low	low to none
Ability to use cottonoids	yes	no	no	n/a	n/a
Reduced bone bleeding	generally observable significant in advanced osetotomies	n/a	n/a	n/a	n/a
Thermal consideration	control irrigation & exposure time	control ancilliary irrigation	control ancilliary irrigation	no	no
Repetitive hand fatigue	low	low	low	low	very high

Table 1. Comparison of BoneScalpel to other bone cutting tools

with BoneScalpel for intradural spinal pathologies over a 3-year period at Johns Hopkins. Successful laminoplasty was carried out in all 40 cases. One case of intra-operative durotomy was noted, which was repaired primarily with no neurological or clinical sequelae. They comment that this “occurred during the user’s first experience with the device and was visualized as a linear heat-related defect likely due to excessive downward pressure after the inner laminar cortex had been cut.” There were no cases of post-operative instability within the follow-up period. The authors plan to perform longer-term studies with imaging at pre-determined time-points to determine whether the thinner laminar cuts produced by BoneScalpel improve osteointegration after laminoplasty. Nickele et al. at University of Wisconsin recently published a similar albeit smaller report on laminoplasty for intradural spine pathologies and have drawn similar conclusions (6).

Lieberman and Hu at Texas Back Institute reported their experience with their first 58 BoneScalpel spine cases in 2012 (7), and subsequently released their expanded data on 128 cases, age range: 12 - 85 years (8). Their case series includes a variety of diagnoses, listed in Table 2. All of the operations were performed by a single surgeon. The device was used at all levels of the spine and the average levels operated on each patient were five. The authors detected “a noticeable absence of bleeding from the cut end of the bone” in these extensive multi-level operations. Two incidental durotomies occurred, one due to thermal injury after prolonged dural contact and the other due to adherence of dura to bone in a revision case. In both cases the dura was successfully sutured in water-tight fashion. No neural injury occurred. The authors concluded: “BoneScalpel is a safe and effective device that can be used in a variety of spine surgeries. This device eliminates the risk of soft tissue injury associated with high speed burrs and oscillating saws during spine surgery.”

Primary Diagnosis	Cases
Spinal stenosis	24
Degenerative scoliosis	15
Pseudoarthrosis	15
Adjacent segment degeneration	11
Idiopathic scoliosis	11
Degenerative spondylolisthesis	10
Disc herniation	9
Flat back syndrome	7
Metastatic spine tumor	5
Vertebral compression fracture	3
Congenital scoliosis	2
Kyphosis	2
Loosened hardware	2
Sacral fracture	2
Scheuermann's kyphosis	2
Spinal spondylosis	2
Spinal tumor	2
Multiple myeloma	1
Vertebral sarcoma	1
Epidural hematoma	1
Pseudoarticulation	1
Total cases	128

Table 2. Diagnoses in the series of Lieberman and Hu at Texas Back Institute

As surgeons gain experience with BoneScalpel, new frontiers are explored. An interesting report from the Czech Republic describes a minimally invasive operation wherein the spinous process is longitudinally divided with BoneScalpel to perform an “elastic laminoplasty” by using a custom-designed retractor to spread apart the two hemilaminae (9). Recently, the Johns Hopkins group reported the use of BoneScalpel in combination with an endoscope to perform minimally-invasive craniostomy surgery (10). Oral-maxillofacial surgeons and otolaryngologists have reported extensive and favorable experience with BoneScalpel while performing mandible osteotomies and harvesting osteocutaneous flaps to reconstruct oncologic defects (11-13). They too have noted the benefits of thin and precise bone cuts, reduced bleeding, and reduced soft tissue and neural injury.

The experience of the author (Pakzaban) with BoneScalpel is presented in Table 3. From 2010 through 2013, the author performed 218 operations with BoneScalpel, encompassing posterior and anterior approaches to cervical, thoracic and lumbosacral spine. There were 97 men and 121 women. Mean age was 51 years (range 19 - 79). The majority were posterior approaches for degenerative disease. TLIF procedures are disproportionately represented here because of the extreme usefulness of Bonescalpel in performing a rapid and bloodless facetectomy. BoneScalpel was also used for rapid and bloodless iliac crest bone graft harvest, often in combination with another BoneScalpel application in this series.

Primary Diagnosis	Cases
Laminectomy/laminotomy for degenerative disease or other extradural pathology	114
Laminectomy for intradural pathology	19
Facetectomy with or without adjacent laminectomy for TLIF	42
Anterior cervical corpectomy	11
Anterior thoracolumbar corpectomy	4
Cranial	12
Iliac crest bone graft harvest (*plus 29 in combination with another BoneScalpel procedure)	16*
Total cases	218

Table 3. Pakzaban's BoneScalpel case series

Four durotomies have occurred in the author's experience (incidence 1.8 %). All were limited linear cuts less than 5 mm in length. In all cases after the durotomy was noted along the cut edge of bone, the BoneScalpel was again used to remove an adjacent slice of bone to permit dural repair. All durotomies were readily repaired with sutures in primary fashion. None of these 4 cases experienced a post-operative cerebrospinal fluid leak or pseudomeningocele formation. None experienced neural injury or other adverse clinical sequelae as a result of BoneScalpel use. The first two occurred early in the author's experience due to aggressive axial pressure resulting in overheating of the blade and subsequent prolonged contact with dura after bone penetration. The other two occurred in the setting of epidural fibrosis resulting in adherence of dura to the inner bone cortex. In

another revision case, the author was able to use BoneScalpel to cut the lamina without penetration of the underlying adherent dura but was not able to elevate the block of bone for fear of dural laceration and had to resort to burring down the loose lamina. Since then, the author has avoided the use of BoneScalpel when the dura is adherent to the bone.

With increased experience, the author has developed formal cutting plans for each operation to maximize efficiency and safety in each case (1, 14). These are described in the following section. Videos of representative operations performed by the author can be viewed at <http://bonescalpel.misonix.com>.

The vast majority of the author's operations and other published reports have been performed with the blade tip. However, the shaver tip is also very useful when a small amount of bone needs to be removed adjacent to a critical structure. The author is currently accumulating a case series of anterior cervical foraminotomies in which the shaver tip is used to perform a complete unciniate process resection adjacent to the vertebral artery. The author has also used Bonescalpel in 12 cranial operations to cut cranial bone ridges such as the rim of foramen magnum, the internal occipital crest, the sphenoid wing, the zygomatic arch, the orbital rim, and the anterior and posterior tables of the frontal sinus. A smaller BoneScalpel hand-piece has been proposed and would significantly enhance the usefulness of BoneScalpel and its shaver tip in intracranial operations, such as removal of anterior clinoid process in aneurysm surgery.

The author's impression of BoneScalpel is consistent with other published reports detailed above. The greater efficiency achieved by *en bloc* bone resection, reduced bone debris, the opportunity to use the harvested bone blocks for grafting, the thin cuts that promote osteointegration after laminoplasty, and (most importantly) soft-tissue preservation have all been mentioned previously. Even in the rare and possibly avoidable instances when a durotomy has occurred, it has been of no consequence. In contrast, dural penetration by a rotating burr poses a far greater risk of major dural lacerations and catastrophic neural injury.

Operative Approaches

The following cutting plans are merely suggestions. They are intended only to serve as examples of how one would approach different bone cutting projects. Each surgeon should develop his or her own plan, on a case-by-case basis, based on the specific surgical anatomy and pathology of the case.

As an additional resource, surgical videos demonstrating many of these approaches are provided at <http://bonescalpel.misonix.com> and referenced below when appropriate. It must be emphasized that the recommendations in this paper and accompanying videos should not be viewed as sufficient and adequate training for performing the illustrated operations. As with all surgery, a stepwise progression from simple to complex, cadaver work, and expert-supervised surgery are recommended.

Lumbar Laminotomy

<http://bonescalpel.misonix.com/video/49468198>

A minimum of 3 cuts are required: 1) a sagittal cut along the base of spinous process, 2) a sagittal cut along the medial rim of the facet joint, and 3) a transverse cut in the lamina to connect the previous two cuts (Fig. 7A).

When the exposure has been obtained through a small skin incision, one will find it easier to divide this project into two pieces. After making the two sagittal cuts, consider making a transverse cut lower on the lamina to remove the lower half of the laminotomy block (Fig. 7B). This provides better exposure of the upper half of the laminotomy block, which sits deeper in the wound. The latter is mobilized and removed after a second transverse cut, higher on the lamina.

When a hypertrophic facet joint is present, one may arrange the cuts differently (Fig. 7C). Consider making the second sagittal cut more medially than you would otherwise, over the thinner portion of lamina, to remove the laminotomy block. Then make an additional sagittal cut along the medial aspect of the facet joint, removing a slice of the latter. Visualization of ligamentum flavum and dura after the first step aids with the deeper bone cutting that is required in the second step.

Lumbar Laminectomy

<http://bonescalpel.misonix.com/video/49468199>

If one intends to remove only the inferior 2/3 of the lamina, this can be achieved with 3 cuts: two sagittal cuts along either side of the spinous process, followed by an axial cut across the top of the spinous process (Fig. 8). Of course, it may be easier to remove the spinous process with a rongeur prior to making the laminar cuts.

If one plans to remove the entire lamina, one should consider removing the inferior 2/3 first. Then remove the superior 1/3 as a separate block.

Lumbar Facetectomy

<http://bonescalpel.misonix.com/video/49468196>

A complete lumbar facetectomy may be required with or without an adjacent laminectomy in certain operations, such as transforaminal lumbar interbody fusion.

This can be achieved in a rapid and systematic fashion with 3 cuts. First, a transverse cut is made along the pars interarticularis. Next a sagittal cut is made along the lateral aspect of the lamina (Fig. 9A). These two cuts allow one to disarticulate and remove the inferior articular process.

Once the inferior articular process is removed, the tip of the superior articular process can be amputated with a single cut (Fig. 9B), thus providing a pedicle-to-pedicle exposure of the neural foramen and disc.

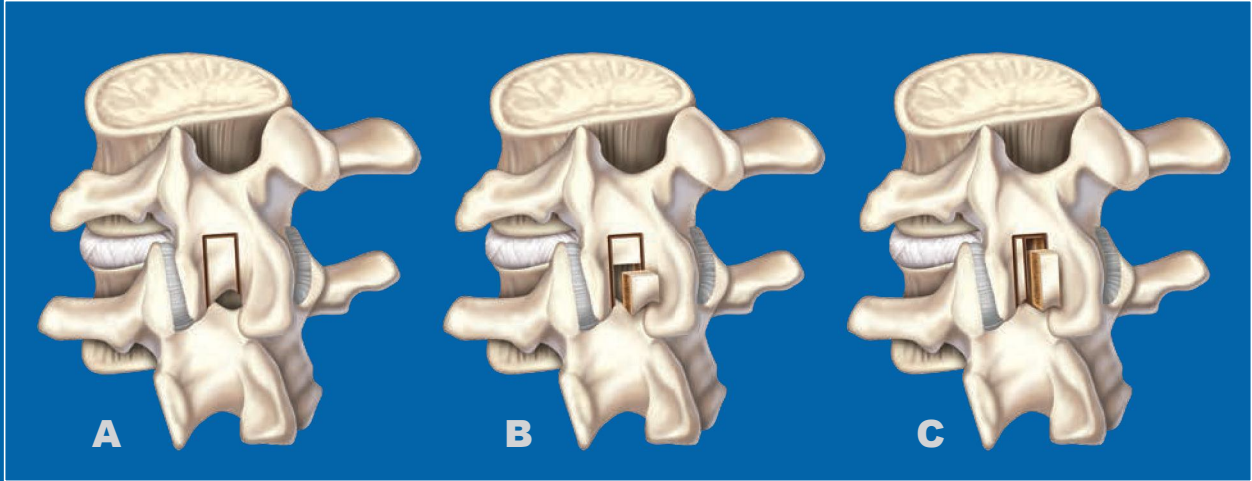


Figure 7. Lumbar laminotomy

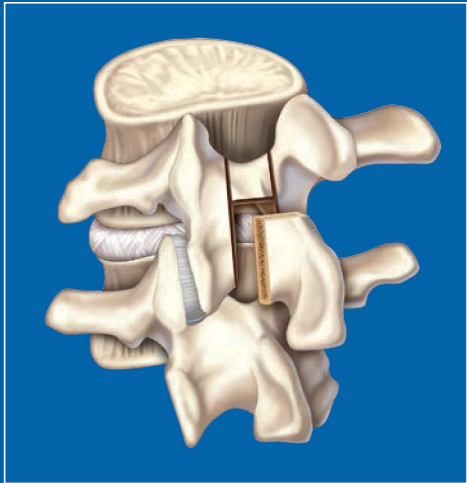


Figure 8. Lumbar laminectomy

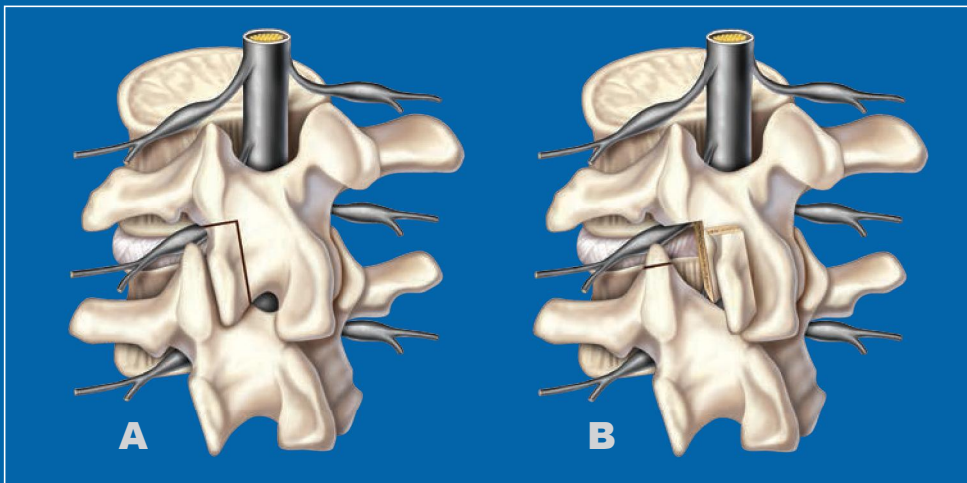


Figure 9. Lumbar facetectomy

Cervical Laminectomy and Laminoplasty **(<http://bonescalpel.misonix.com/video/49458768>)**

A multilevel cervical laminectomy can be performed expeditiously with BoneScalpel by making 2 parallel cuts on either side of multiple laminae (Fig. 10).

For open-door laminoplasty, one should not penetrate the inner bone cortex on the “hinge” side. The hinge side can be prepared with a drill. Alternatively, one can use BoneScalpel on the hinge side to make two closely-approximated outer-cortical cuts which intersect at their depth (with a V-shaped profile), then remove the wedge of outer-cortical bone to allow the hinge to open (Fig.11).

Anterior Cervical Corpectomy **(<http://bonescalpel.misonix.com/video/50303878>)**

After discectomies have been carried out above and below the level(s) of interest, it is recommended that the anterior portion of the vertebral body be removed first. To achieve this, parallel cuts are made on either side of the vertebral body (Fig. 12A), stopping short of the posterior wall and the posterior osteophytes (Fig. 12B). The anterior aspect of the vertebral body delimited by the two cut planes and the two disc spaces can be removed with a large rongeur (Fig. 12C). The removal of this bone provides for better exposure and greater control as BoneScalpel is used to make parallel cuts through the posterior wall. The posterior wall is then carefully elevated and removed (Fig. 12D).

Caution must be exercised to avoid plunging with BoneScalpel, particularly in a stenotic canal with cord compression. During elevation of the posterior wall, one must avoid rocking one end of the bone into the spinal canal as the other end is being elevated. Finally, this technique is not suitable for circumstances where the dura may be adherent to the posterior wall, as in ossification of posterior longitudinal ligament.

Anterolateral Lumbar or Thoracic Corpectomy

This is an advanced BoneScalpel technique that should be attempted only after the surgeon has developed competence and confidence with the use of BoneScalpel in other operations.

The technique for removal of a thoracic or lumbar vertebral body through an anterolateral approach is dependent on the pathology for which the operation is being performed. Often tumors and infections will have softened the bone to the point that removal of the mid-portion of the vertebral body does not present a challenge. If necessary, BoneScalpel can be used in combination with rongeurs and drills to facilitate this step. Thorough removal of bone in this step (to get as close as possible to the posterior vertebral body wall) will facilitate the subsequent steps.

The main challenge is removal of the posterior vertebral body wall to expose and decompress the spinal canal. After the neural foramen and pedicle are partially exposed and the mid-portion of the body is removed, a cut is made with BoneScalpel at the junction of the ipsilateral pedicle and vertebral body toward the spinal canal (Fig. 13). A second cut is made through the cavity in the vertebral body toward the contralateral side of the spinal canal. The posterior wall is then carefully elevated away from the canal and removed.

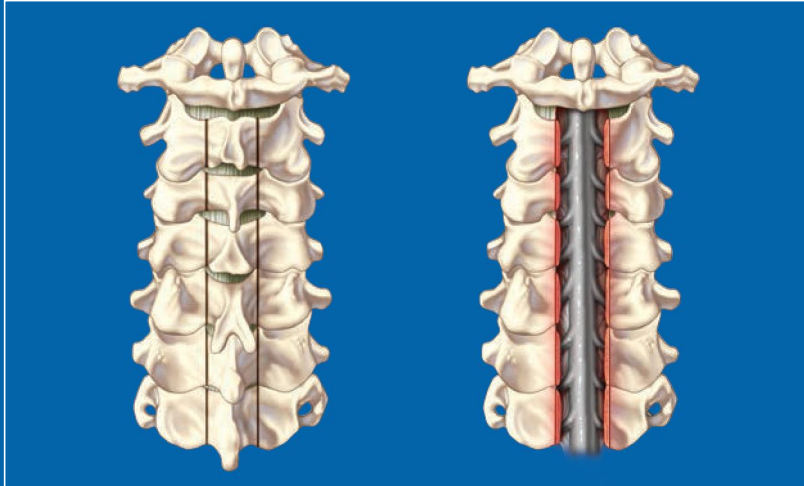


Figure 10. Cervical laminectomy

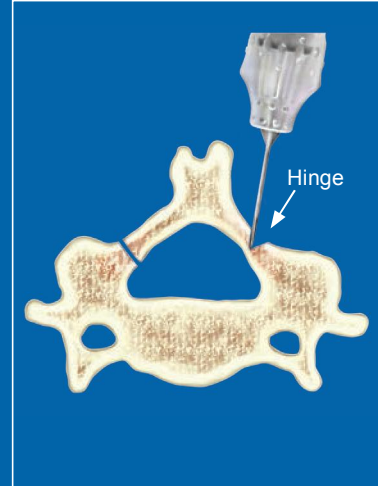


Figure 11. Cervical laminoplasty

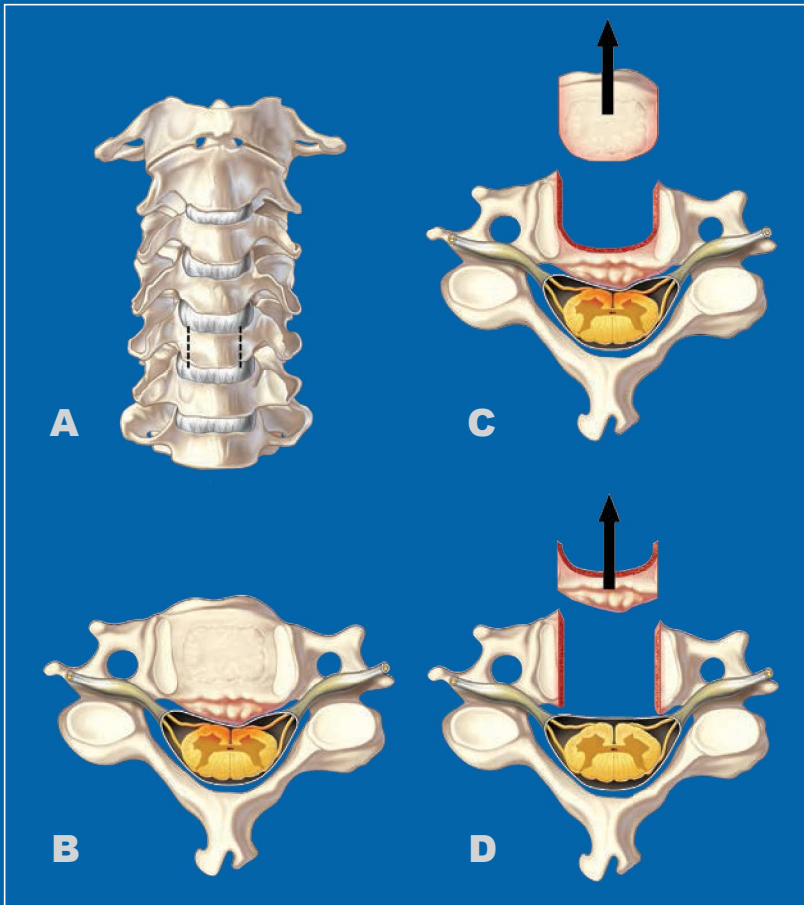


Figure 12. Anterior cervical corpectomy

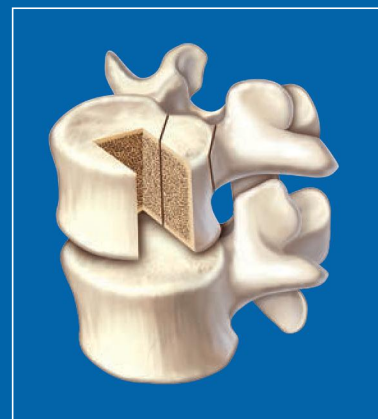

Figure 13. Lumbar or thoracic corpectomy

Economic Impact

In a cost-conscious healthcare environment it is expected that hospitals and surgical facilities would scrutinize the economic impact and value of new technologies. The routine use of BoneScalpel has resulted in significant cost savings in the author's practice. The ability to harvest autologous bone *en bloc* during laminectomies and facetectomies and utilize that bone for fusion has significantly reduced the author's reliance on expensive fusion supplements such as recombinant bone morphogenic protein (BMP) and implanted bone stimulators. The reduction in bleeding during multilevel laminectomies has reduced the use of cell savers and the rate of blood transfusions.

Most importantly, the reduced risk of cerebrospinal fluid leak and neurological injury is expected to have significant economic benefits, such as reduced use of tissue sealants, diminished length of hospital stay, and reduced rate of readmissions and reoperations for CSF complications. Increasingly, pay-for-performance insurance models levy penalties for "avoidable" complications such as urinary catheter and intravascular line infections. It may not be long before payment is denied for readmissions or prolongations of stay due to iatrogenic surgical complications such as cerebrospinal fluid leaks. As value-based purchasing becomes the norm in the health insurance industry, technologies that promote safety and reduce complications will become even more economically attractive.

Future Developments

Ultrasonic bone dissection technology continues to evolve. As more surgeons adopt this technology, more enhancements will occur to meet the varied demands of a growing market. A portfolio of cutting tips is being developed to give surgeons greater choice and flexibility for different bone dissection projects. A smaller hand-piece, ergonomically similar to modern drills, is eagerly anticipated. A low profile hand-piece will significantly increase BoneScalpel's range of applications and would facilitate its use in microsurgical, mini-open, minimally invasive, and intracranial cases.

Conclusions

BoneScalpel is a safe and effective ultrasonic bone dissector that will soon become an integral part of the armamentarium of every well-trained spine surgeon. It offers distinct advantages in comparison to power drills and hand instruments that make it well-suited to many bone cutting projects in spine surgery. While in certain operations it may replace the drill altogether, in many cases it will be used alongside the power drill and manual rongeurs.

The safe and effective use of this device requires development of a tactile feel for when the inner cortex of the bone is penetrated. The relative selectivity of this ultrasonic device for cutting bone in preference to soft tissues allows safe contact with the underlying dura for a limited time and offers a margin of safety when the inner cortex is penetrated. It is important to understand that pathological changes such as epidural adhesion limit this tissue selectivity. The ability to remove bone pieces *en bloc* offers many advantages but requires planning the bone cuts in advance.

The learning curve is short. Once the tactile feel and *en bloc* bone elevation techniques have been mastered, bone resection is performed with a degree of elegance, efficiency, and safety surpassing other methods of bone removal.

Disclosure

Peyman Pakzaban, M.D. is a board-certified neurosurgeon in private practice at Houston MicroNeurosurgery in Houston, Texas, and Chairman of Surgery at Bayshore Medical Center. He serves as an educational and research consultant for Misonix Inc., Aesculap, Inc. and other spine technology companies.

References

1. Pakzaban P. BoneScalpel™ Ultrasonic Bone Cutting System: Neurosurgical and Orthopaedic Applications, Aesculap Power Systems, www.aesculapusa.com, 2012
2. Sanborn MR, Balzer J, Gerszten PC, Karausky P, Cheng BC, Welch WC. Safety and efficacy of a novel ultrasonic osteotome device in an ovine model. *J Clin Neurosci*. 2011 Nov;18(11):1528-33. Epub 2011 Sep
3. Recinos VR, Ahn E, Carson B, Jallo G. Technical Note: A Novel Bone-Cutting Instrument, the BoneScalpel™, May be Useful in Performing Osteoplastic Laminoplasty. AANS/CNS Section on Pediatric Neurological Surgery Annual Meeting, Boston, MA, December 2009.
4. Parker SL, Kretzer RM, Recinos PF, Jallo GI, Recinos VR. Use of a Novel Ultrasonic Bone Scalpel for Osteoplastic Laminoplasty in the Resection of Intradural Spinal Cord Pathology. 27th Annual Meeting of the AANS/CNS Section on Disorders and Peripheral Nerves, Phoenix, AZ, March 2011
5. Parker SL, Kretzer RM, Recinos PF, Molina CA, Wolinsky JP, Jallo GI, Recinos VR. Ultrasonic Bone Scalpel for Osteoplastic Laminoplasty in the Resection of Intradural Spinal Pathology: Case Series and Technical Note. *Neurosurgery*. 2012 Dec 20.
6. Nickele C, Hanna A, Baskaya MK. Osteotomy for Laminoplasty without Soft Tissue Penetration, Performed Using a Harmonic Bone Scalpel: Instrumentation and Technique. *J Neurol Surg A Cent Eur Neurosurg*. 2013 Mar 15.
7. Lieberman IH, Hu X. Use of Ultrasonic BoneScalpel in Spine Surgeries: Experience from the First 58 Patients. 19th International Meeting on Advanced Spine Techniques (IMAST), Istanbul, Turkey, July, 2012
8. Hu X, Ohnmeiss DD, Lieberman IH. Use of an ultrasonic osteotome device in spine surgery: experience from the first 128 patients. *Eur Spine J*. 2013 Apr 16.
9. Suchomel P, Hradil J. [Minimally invasive cervical elastic laminoplasty - principles and surgical technique]. *Acta Chir Orthop Traumatol Cech*. 2011;78(5):437-41. Czech.
10. Chalchana KL, Jallo GI, Dorafshar AH, Ahn ES. Novel use of an ultrasonic bone-cutting device for endoscopic-assisted craniosynostosis surgery. *Childs Nerv Syst*. 2013 Feb 6: DOI 10.1007/s00381-013-2043-6. [Epub ahead of print].
11. Gilles R, Couvreur T, Dammous S. Ultrasonic orthognathic surgery: enhancements to established osteotomies. *Int J Oral Maxillofac Surg*. 2013 Jan 8.
12. Wick CC, Rezaee RP, Zender CA. Piezoelectric BoneScalpel osteotomies in osteocutaneous free flaps. *Laryngoscope*. 2013 Mar;123(3):618-21. Epub 2012 Sep 24.
13. Dammous S, Gilles R. Use of Ultrasonic Straight Blade in Orthognathic Surgery: Review of 75 Patients. *Int J Oral Maxillofac Surg*. 2011 40 (10): 1082.
14. Pakzaban P. BoneScalpel™ in Spine Surgery. Surgical Technique and Operative Approaches, Aesculap Power Systems, www.aesculapusa.com, 2011



1938 NEW HIGHWAY, FARMINGDALE, N.Y. 11735 | +1.631.694.9555 +1.631.694.3285 FAX
MISONIX, INC. | NASDAQ SYMBOL. MSON | MISONIX.COM